

Mechanisms involved in wound healing

Wounds and skin damage are subjects of great importance to the dermal pharmaceutical and skin care industries, but the injuries caused and the repair mechanisms involved are also important in the laboratory setting, as Pascal Mallefet and Anthony C Dweck explain.

A wound occurs when the integrity of any tissue is compromised (eg skin breaks, muscle tears, burns or a bone fracture). A wound may be caused as a result of a fall, a surgical procedure, an infectious disease or an underlying pathological condition.

Types and causes of wounds are wide ranging, and healthcare professionals have several different ways of classifying them. They may be chronic, such as the skin ulcers caused by diabetes mellitus, or acute, such as a gunshot wound or animal bite.

Wounds can be open, in which the skin has been compromised and underlying tissues are exposed, or closed, in which the skin has not been compromised, but trauma to underlying structures has occurred (eg a bruised rib or cerebral contusion). Emergency personnel and first-aid workers generally place acute wounds in one of eight categories:

- **Abrasions**, also called scrapes, which occur when the skin is rubbed away by friction against another rough surface (eg rope burns and skinned knees)
- **Avulsions** occur when an entire structure or part of it is forcibly pulled away, such as the loss of a permanent tooth or an ear lobe; animal bites may cause avulsions
- **Contusions** (bruises) are the result of a forceful trauma that injures an internal structure without breaking the skin; blows to the chest, abdomen or head with a blunt instrument (eg football or fist) can cause contusions
- **Crush wounds** occur when a heavy object falls on a person, splitting the skin and shattering or tearing underlying structures
- **Cuts** are slicing wounds made with a sharp instrument, leaving even edges; they may

be as minimal as a paper cut or as significant as a surgical incision

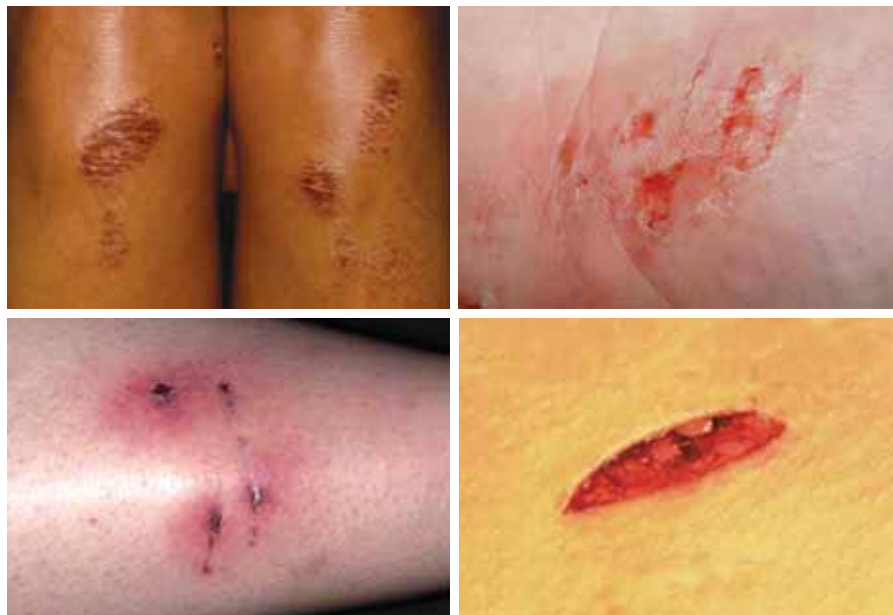- **Fish-hook wound**: an injury caused by a fish-hook becoming embedded in soft tissue
- **Incised wound**: any sharp cut in which the tissues are not severed; a clean cut caused by a keen cutting instrument – the wound may be aseptic or infected, depending on the circumstances
- **Lacerations** (tears) are separating wounds that produce ragged edges; they are produced by a tremendous force against the body, either from an internal source as in childbirth, or from an external source such as a punch

- **Open wound** (contusion) in which the skin is also broken, such as a gunshot, incised or lacerated wound
- **Penetrating wound** in which the skin is broken and the agent causing the wound enters subcutaneous tissue or a deep lying structure or cavity (the agent might be a nail, splinter or spike)
- **Punctures** are deep, narrow wounds produced by sharp objects such as nails, knives and broken glass.^{1,2}

WOUND HEALING

Skin trauma will start an organised and predictable sequence of events that has a cascade effect until the wound is bridged by scar tissue that binds and holds the wound in stasis.

Successful treatment minimises the formation of scar tissue and reduces the amount of necrotic tissue that is produced during this process. The use of hydrogel helps to produce more rapid healing by creating a moist environment that reduces the build up of necrotic tissue through apoptosis (programmed cell death). The beneficial



Clockwise from top left: Abrasions on knees, hands, incised wound and puncture wound.

effects of a moist versus a dry wound environment include the prevention of tissue dehydration and cell death, accelerated angiogenesis, increased breakdown of dead tissue and fibrin (ie pericapillary fibrin cuffs) and potentiating the interaction of growth factors with their target cells.³

The response to injury, either surgically or traumatically induced, is immediate and the damaged tissue or wound then passes through phases in order to effect a final repair. These phases are barrier protection, the inflammatory phase, the fibroplastic phase and the remodelling phase.

PHYSICAL BARRIER

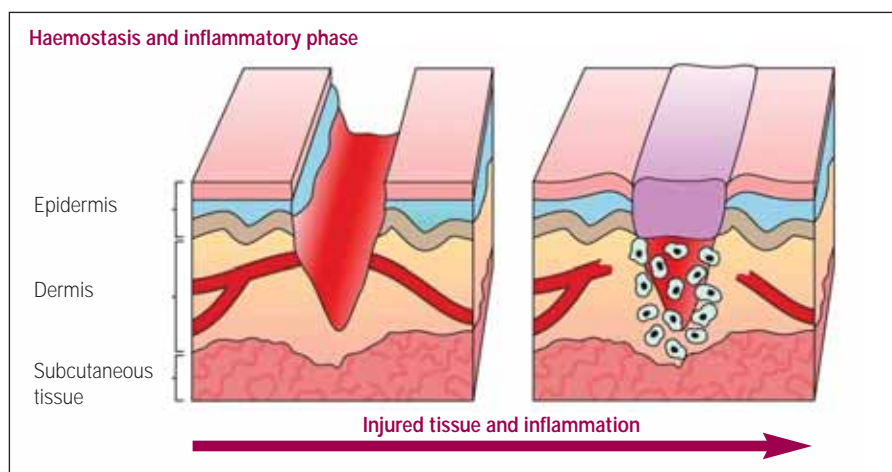
The most important action to take in the case of any wound is to protect it from the external environment and apply some form of a dressing. Modern thinking suggests that wounds should be kept in a moist environment, and hydrogel is a perfect medium to apply.

Wound care should support the natural healing process, and such care should provide a moist dressing/wound interface, absorb or remove excess exudate, provide thermal insulation, prevent contamination and provide an environment conducive to the body's natural defence mechanisms.

Furthermore, dressings should cause little or no discomfort to the patient and be able to remain in place for a number of days to facilitate the healing process and reduce the cost of care.⁴

Occlusion dressings can minimise necrotic tissue by preventing desiccation, aiding debridement, and providing a barrier against exogenous pathogenic organisms, thus limiting the resulting inflammatory cascade.⁵ The use of more moisture-retentive dressings generally achieves environments supportive of earlier healing when compared to less moisture-retentive dressings.

Maceration, an unwelcome occurrence with moisture-retentive dressings on highly exuding wounds, is not consistently associated with increased adverse events. Evidence suggests that greater dressing moisture retention is associated with fewer clinical infections, greater patient comfort and reduced scarring.⁶ Concerns that moisture in wounds would increase the risk of clinical infection over traditional therapies are unfounded.^{3,7}



Wounds will readily acquire bacteria unless protective measures are taken. The bacterial protection afforded by conventional absorbent cellulose dressings is limited, particularly in the presence of serous exudate that may compromise dressing integrity. In addition, dressings may shed particles that remain in the wound. In contrast, many modern dressings are impermeable to bacteria, are removed completely, have been found to optimise re-epithelialisation rates and reduce the incidence of wound sepsis.

Furthermore, the numbers of bacteria per litre of air following removal of hydrocolloid dressings were approximately 20% of those observed with gauze.⁸

The sense of touch is provided by a network of nerve endings that reach just about every part of the body. These sensory nerve endings are located just beneath the skin and register light and heavy pressure on the skin and also differences in temperature. These nerve endings gather information and send it to the brain. A graze to the skin will likely remove both the stratum corneum and in more severe cases the underlying epidermis as well. This will almost certainly expose nerve endings in the skin and so heighten their sensitivity so that they become extremely sensitive.

The application of hydrogel will provide a soothing barrier that insulates the wound against hot and cold stimuli and also act as a cushion against external physical influences such as pressure and touch.

Hydrogel provides a cooling barrier that permits water to evaporate from the surface

and so produce a cooling effect. It is this cooling effect that helps to reduce the microcapillary circulation to the surface of the skin, so encouraging a reduction in erythema (redness), may lessen the build up of oedema and so reduce swelling to allow more even wound healing. This cooling effect will bring soothing comfort.⁹

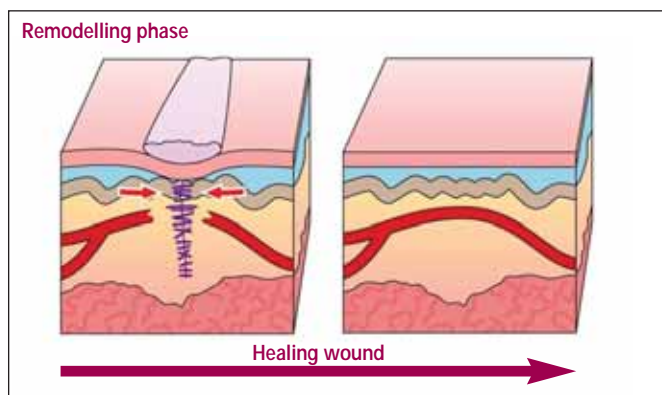
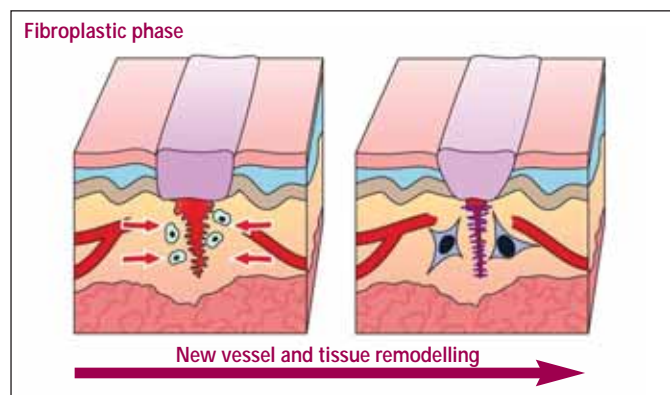
Pain is significantly reduced when wounds are covered with an occlusive dressing.^{3,10,11} Frequent dressing changes are time consuming and sometimes painful, but patients are able to move freely and take showers, and nursing time spent on changing post-operative dressings is greatly reduced.¹² Dressings with large absorptive capacity reduce pain related to maceration of surrounding tissues and to pressure caused by the excess exudates.¹³

INFLAMMATORY PHASE

The inflammatory phase prepares the area for healing and immobilises the wound by causing it to swell and become painful, so that movement becomes restricted. The fibroplastic phase rebuilds the structure, and then the remodelling phase provides the final form.

Tissues can heal at different rates, and even one wound can show various areas healing rapidly or slowly. The more rapid the healing process can be made leads to the better likelihood of a satisfactory outcome. The use of a moist healing environment has been demonstrated to speed up the healing process when compared to a dry dressing scenario.

Scar quality is significantly superior in those wounds treated with a moist dressing.¹⁴



Scar assessment scores demonstrated marked prevention of unfavourable scars with improved cosmetic results following prophylactic use of a moist hydrogel-type dressing.¹⁵ The rate of wound infections is not increased when occlusive dressings are used following surgery. Finally, occlusive dressings have also been found to reduce inflammation and subsequent scarring.^{12,16}

Inflammation is a normal and necessary prerequisite to healing. Changes in vascular flow are responsible for the clinical symptoms used to detect an inflammatory response. The majority of the specialised cells involved in this phase of the wound healing process come from blood.

Blood vessels that traversed the wound are severed at the time of injury and it is these cut vessels that allow whole blood into the wound, which then coagulates, seals the injured vessels and lymphatic channels in order to close the wound, and prevents further haemorrhage. The simultaneous release of histamine and other triggers by the injured tissue causes the intact vessels to dilate.

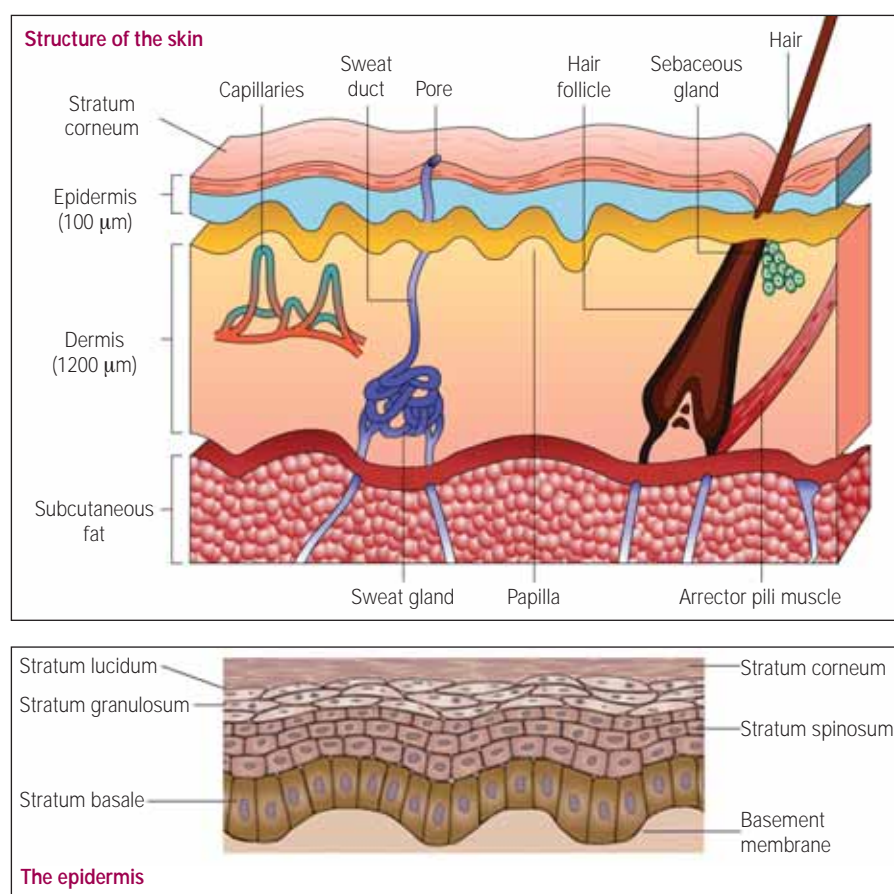
Histamine causes brief vasodilation in neighbouring non-injured vessels and it is this combination of whole blood exudate and serous transudate that creates a reddened, hot, swollen and painful environment. Bradykinins, derived from plasma in the area of the injury, contribute to more prolonged vascular permeability.

Prostaglandins are produced by all cells in the body and are released when there is any disruption of cell membrane integrity. Certain prostaglandins further contribute to long-term vascular vasodilation. The fibrin plugs that clot in the wound to seal leakage also form in the lymphatic vessels. The blocking of the lymphatic flow not only seals the wound but also helps to stop the spread of infection. They remain closed until later in the healing process.

Mast cells also release hyaluronic acid and other proteoglycans into the cocktail of chemicals accumulating within the wound and these bind with the watery wound fluid to create a non-flowing gel that slows down leakage and fluid loss. The inflammatory oedema fills up all the spaces in the wound and surrounds all the damaged or repaired structures and binds them together.

This type of oedema causes loss of dermal fat, thus thinning normal skin in the area. Some swelling in a wound is inevitable and to a degree it is required for successful healing to occur. If there is no inflammation then healing does not begin, and if too little inflammation occurs then healing may be slow. However, if too much inflammation occurs then the likelihood of excessive scarring increases. This inflammatory fluid, derived from the blood, is high in fibrinogen, which coagulates in the wound and in the surrounding tissues that are now filled with fluid. Later, the coagulated fibrin will mature into a dense, binding scar.

The soluble protein fibrinogen circulates in the blood and provides the material from



which the insoluble fibrin clot is formed during blood coagulation. Fibrinogen, as an acute-phase reactant, responds to infection and other short-term inflammatory stressors.

Excessive swelling, therefore, must not be permitted. Primary wound care ensures that all blood vessels have been repaired, cauterised or clotted. Haematomas, the result of ongoing bleeding in the wound, create extra exudate, which is a powerful stimulus to scar formation.

The application of hydrogel provides a vehicle into which the exudates may migrate and dissolve, thus removing it from the wound site without drying out the wound and allowing the formation of potential scar tissue to be reduced. The use of hydrocolloid dressings facilitates granulation tissue formation. Also, the use of these dressings solves many of the practical problems associated with traditional methods of keeping metal plates, exposed bone and tissues moist.¹⁷

Secondary wound care addresses the contribution made by induced vasodilation, which continues in relation to the severity of the wound. This serous transudate can be diminished by a regimen of rest, ice, compression and elevation.

Pharmacological use of steroids and aspirin affects the transudative oedema, and their action inhibits prostaglandin release. All wounds, and even controlled surgical procedures, require oedema care.

For healing to commence, the wound must be decontaminated by phagocytosis, and a

new blood supply (neovascularisation) must then be available.

PHAGOCYTOSIS

Within blood vessels adjacent to the wound, white blood cells start to adhere to the dilated endothelial walls. Chemical changes in the wound induce and attract these cells to slip through the enlarged capillary pores and migrate to the site of injury. The main purpose of this phase is to prevent infection or rid the wound of infective agents. All wounds, even under meticulous sterile conditions, are contaminated.

Fortunately, the system of defence is perfectly adequate to prevent a minor contamination from developing into a major infection. Certain conditions can encourage an infection to develop. The types of bacteria present, the presence of foreign objects, necrotic tissue, poor oxygen supply, malnutrition, certain vitamin deficiencies, radiated tissues, and immunosuppression may all lead to complications.

The first white blood cells to reach the wound are polymorphonuclear leucocytes. These short-lived cells begin the process of phagocytosis by fixing to bacteria, extending their membrane around them, then enzymatically dissolving and digesting the invaders.

Phagocytosis is the cellular process of engulfing solid particles by the cell membrane to form an internal phagosome (food vacuole) and is a major mechanism used to remove pathogens and cell debris.

Within a few days of the injury, another type of phagocyte will predominate and remain in the wound until all signs of inflammation cease. This cell, the macrophage, has two important roles in the process of repair. Macrophages are cells in the tissues that originate from specific white blood cells called monocytes. Their role is to phagocytose cellular debris and pathogens, either as stationary or mobile cells, and to stimulate lymphocytes and other immune cells to respond to the pathogen.

The macrophage has considerable influence on scar production. As a scavenger cell, the macrophage not only attacks and engulfs bacteria but also disposes of necrotic tissue in the wound. It is also capable of phagocytosing in poorly nourished tissues with low oxygen levels or can consume oxygen at over 20% of the basal rate for enhanced phagocytosis. Because ischaemic tissues are more prone to infection than normal tissues, the oxygen state of the wound is a critical factor.

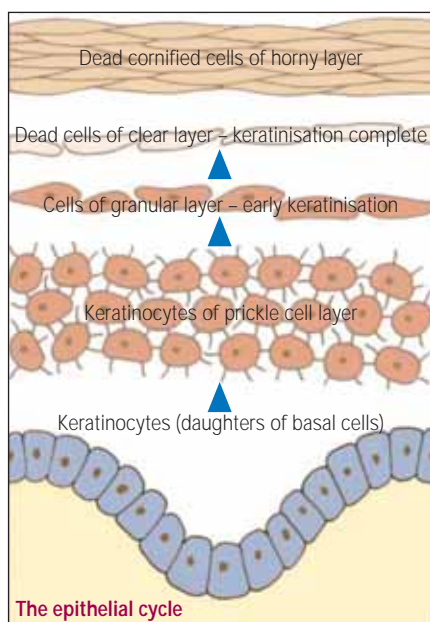
Ischaemia is a restriction in blood supply, generally due to factors in the blood vessels, with resultant damage or dysfunction of tissue.

The maintenance of an adequate arterial oxygen supply for optimum phagocytosis is dependent on a sufficient blood volume and is also a function of the percentage of atmospheric oxygen breathed (as opposed to local, topically applied oxygen). Macrophages ingest microorganisms and excrete products of digestion (ie ascorbic acid, hydrogen peroxide and lactic acid) as a result of phagocytosis.

Hydrogen peroxide aids in controlling anaerobic microbial growth, while the level of ascorbic acid and lactic acid are interpreted as a need for more macrophages. The cycle involves more macrophages producing more by-products and so leads to a more intense and prolonged inflammatory response.

Most wounds heal without infection because of the microbiocidal capacity of the macrophage population. Chronically activated macrophages create a chronically inflamed wound. Hydrogel can mitigate this process by assisting the macrophage in its work by providing a moist, exudate-solubilising environment.

Soon, fibroblasts respond to the chemical signals issued by macrophages. Fibroblasts provide a structural framework for many tissues, play a critical role in wound healing and are the most common cells of connective tissue. They secrete the precursors of all the components of the extracellular matrix,



primarily the ground substance and a variety of fibres.

The macrophage influences repair by chemically influencing the number of fibroblastic repair cells activated. It is a local platelet-derived growth factor released from the platelets during clotting and from macrophages that signals fibroblasts. The macrophage is a key factor in regulating the stages of the inflammatory period. Its presence is vital as a phagocytic agent and an appraiser of damage, and the presence of fibroblasts is significantly related to the final amount of scar produced.

It is of interest to note that the use of steroids may inhibit the macrophage level and result in a lowering in the rate of wound debridement and so lead to a delay in scar production.

Neovascularisation is the growth of new blood vessels, as healing will not proceed unless new, functioning blood vessels are present to supply oxygen and nourishment to the injured tissue. It is likely that macrophages signal this vascular regeneration to begin. Patent vessels in the outlying wound area develop small 'buds' or 'sprouts' that grow into the wound area and it is these outgrowths that eventually will come into contact and join up with other arteriolar or venular buds to form a functioning capillary loop.

These new circulatory loops fill the wound, creating a pink/red colour throughout the wound. As a result, the young wound will

remain much redder in contrast to adjacent tissues throughout healing because of the high concentration of capillary loops. Those areas that remain grey in appearance or show delayed whitening following pressure have an inadequate circulation. As the wound approaches final maturity the majority of these loops cease to function and they retract. As a result, the fully matured scar appears whiter than adjacent tissue.

The success of wound healing may therefore be determined by the colour of the scar and be a guide to the prognosis of any further changes in scar characteristics. The capillary sprouts, when first formed, lack full thickness, which renders them delicate and easily disrupted, so immobilisation is essential during this phase to permit vascular regrowth and prevent the formation of microhaemorrhages. As this phase comes to a close, fibrinolysin in blood vessels is produced to assist in dissolving clots and the lymphatic channels open to assist in reducing the wound oedema.

Under normal conditions, all these events happen within the first four days after injury and the main objective in treatment is to minimise all the factors that can prevent or prolong inflammation.

FIBROPLASTIC PHASE

With the inflammatory phase completed, rebuilding can commence. This phase is named after the primary cell of scar production, the fibroblast.

Many different cells are involved in the inflammatory phase, but fewer types of cell operate in the fibroplastic phase, which lasts for about three weeks. During this phase the wound is resurfaced and strength is imparted to the wound. The fibroblasts originate from mesenchymal cells located in loose tissue around blood vessels and fat. In response to chemotaxis, fibroblast precursors transform into cells with migratory ability.

These migratory fibroblasts follow the fibrin meshwork created earlier in the wound fluid milieu, which enveloped all injured structures, and thus the fibroblasts have access to all depths of the wound. Once in place, the fibroblast initiates its synthesis of the collagen molecule. During this phase, three processes occur simultaneously to achieve coalescence and closure, and these processes are epithelialisation, wound contraction and collagen production.

Topical application of hydrogel to a wound site enhances wound healing and it has been demonstrated that L-arginine increases

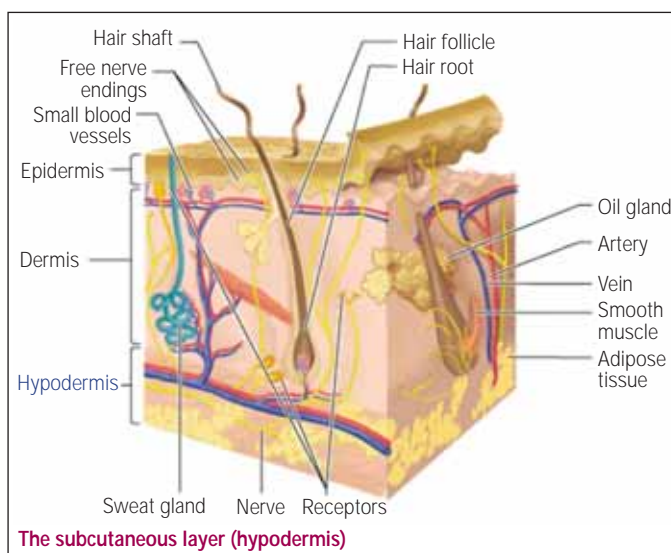
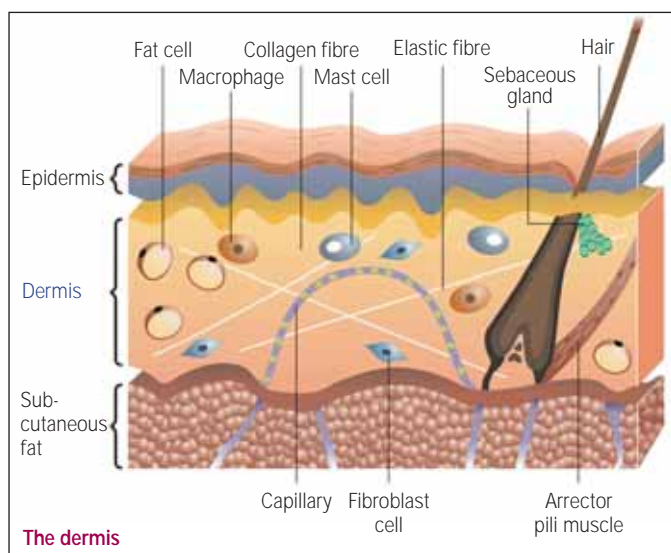


Enjoy the benefits of Company Membership

- Commercial organisations and institutions are invited to join the Institute as Company Members.
- Join biomedical scientists in working to improve standards and communications in the pathology laboratory field.
- Company Members can make their views known through a liaison group.

A brochure is available on request to the IBMS office at: 12 Coldbath Square, London EC1R 5HL.

Tel 020 7713 0214. Fax 020 7837 9658. Email mail@ibms.org or via the website (www.ibms.org).



collagen biosynthesis¹⁸ and reduces apoptosis¹⁹. Arginine is the physiological substrate for NO synthesis, and systemic arginine administration improves wound healing in normal individuals as well as in individuals with impaired wound healing.²⁰

Arginine enhances wound healing and lymphocyte immune responses in humans²¹ and stimulates wound healing and immune function in the elderly.²² Administration of agents known to enhance T-lymphocyte function, such as thymotrophic arginine, leads to increases in wound breaking strength and collagen deposition.^{23,24}

Several studies have reported impaired wound healing after trauma and shock. Wound immune cell dysfunction seems to be responsible for altered wound healing after trauma/haemorrhage. In this respect, administration of L-arginine normalised wound immune cell function under those conditions,²⁵ and was also shown to support the successful wound healing of diabetic ulcers.²⁶ Arginine is beneficial in enhancing wound healing, and was shown to reduce hospital stay in severe trauma patients, with few side effects.²⁷

EPITHELIALISATION

The factors critical to tissue survival are phagocytosis, blood flow and the provision of a surface covering. These events occur early in the healing process. The provision of even a one-cell layer will provide protection from invading organisms. Neuropathic ulcers respond well to reducing the pressure that caused the ulcer, removing necrotic materials and to secure protection with a hydrocolloid dressing. Such wounds have been found to heal, on an out-patient basis, after approximately six weeks. All diabetic foot ulcers are contaminated with a variety of organisms, but antibiotic treatment is usually unnecessary.²⁸

Within hours of injury, undamaged epithelial cells at the wound margin begin to reproduce. Epithelial mitosis causes accelerated reproduction and leads to a ridge forming around the periphery of the wound.

These new cells are true epithelial cells and therefore this represents a regeneration process.

Surviving epidermal structures such as hair shafts and sweat glands also give rise to epithelial mitoses. If the wound bed is viable and a good blood supply is available, then migration of these new cells begins, with those from the periphery moving in and those from appendages moving out. These migratory cells remain attached to their parent cells and their movement causes tension on the normal skin around the wound edge. The advancing edge of the epithelium seeks out moist, oxygen-rich tissue.

If the epithelial edge meets eschar, foreign material, sutures or blood clots, it will plunge under it in order to maintain contact with the vascular loop network in the wound.

The epithelial margin must release lytic enzymes, which act to cleave the attachment of non-viable tissue from the viable wound bed. Thus, this epithelial margin gradually undermines and loosens the eschar, which eventually detaches from the wound.

A red, highly vascular wound with a thin, almost transparent covering appears once the eschar is detached. A scab forms as a temporary barrier for the wound and should not be disturbed until epithelialisation is complete.

If necrotic tissue or the wound is too extensive or oxygen availability is poor, epithelial migration cannot proceed. If sufficient capillary circulation is not available to maintain epithelial integrity then wound dehiscence can occur.

Dehiscence is the premature bursting or splitting of a wound along natural or surgical suture lines. It is a complication of surgery that occurs secondary to poor wound healing. Risk factors include diabetes, advanced age, obesity and trauma during the post-surgical period.

When epithelial cells from one direction meet similar migratory cells from another direction, contact inhibition causes cessation of movement. Although clean, approximated wounds are clinically resurfaced within

48 hours, larger open wounds require a longer period of repair. Several weeks are required for this thin covering to become multilayered and to differentiate into the various strata of the normal epidermis.

The thickening process of skin healing is termed intussusceptive growth. However, skin healed in this manner never truly develops a full basal layer of cells and will always be thinner in appearance.

WOUND CONTRACTION

Epithelialisation closes the wound surface, but contraction pulls the entire wound together, in effect shrinking the defect. A successful contraction results in a smaller wound that needs to be repaired by scar formation.

Minimising the area to be healed is truly beneficial in certain tissues with fixed, deep structures covered by mobile, loose skin. Wound contraction, however, may be harmful in those areas that require every millimetre of skin and tissue length, such as the hands and face.

Allowing uncontrolled contraction is a potential problem as it will distort the topography of the skin and cause the tissue to be drawn abnormally towards the site of healing, causing disfigurement and discomfort. A specialised cell called a myofibroblast is involved in this contraction process. In terms of differentiation, the myofibroblast lies between a fibroblast and a smooth muscle cell.

Myofibroblasts attach to the skin margins, pull the entire epidermal layer inward, and are a feature in hypertrophic scars. Control of wound contraction and scar formation at the time of wound formation is useful in order to control the direction of wound contraction and thus prevent distortion.²⁹

COLLAGEN PRODUCTION

The conclusion to the wound healing process is collagen production, which is essential if wound healing is to occur. Migratory fibroblasts are now present throughout the

wound and it is this environment that stimulates the fibroblasts to synthesise and secrete collagen. The build up of lactic acid influences the amount of collagen produced. Adequate supplies of oxygen, ascorbic acid and other cofactors such as zinc, iron and copper are needed to create the proper background for fibroplasia, which is the production of fibrous tissue, usually implying an abnormal increase of non-neoplastic fibrous tissue.

The fibroblast synthesises three polypeptide chains that coil to form a right-handed helix. These spiralled chains (procollagen) are then extruded from the fibroblast into the extracellular space. Once exocytosed, the triple-helical molecule undergoes cleavage at specific terminal sites and becomes tropocollagen.

Tropocollagens associate spontaneously in an overlapping array and eventually convolve with other tropocollagen molecules to form a collagen fibril. These filaments lay disorganised in the wound and are in a gelatinous state. There is little strength in this collagen mass, which requires crosslinks and other bonding to be formed before wound durability or tensile strength can be achieved.

Fibroblast also synthesises glycosaminoglycans (GAG), which fill in the space between and around collagen. This GAG ground substance, combined with water, provides lubrication and acts as a spacer between moving collagen fibres. New crosslinks are formed that convert mobile tissue into immobile tissue. The relationship between GAG ground substance and collagen dictates the scar architecture. A bulky, rough, tender, red scar is visible and palpable.

Oedema, infection and rough handling can cause the wound to become re-inflamed. Any mobilisation aimed at breaking scar tissue may create a new wound, with further scar formations. A secondary inflamed wound will result in collagen deposition in addition to that already present and so the quantity of scar produced is an indication of the final outcome.

SYNTHESIS-LYSIS BALANCE

Despite the fact that collagen synthesis continues at a high rate, no further increase in scar mass occurs. At this point, new collagen is created and old collagen is broken down in a balanced fashion as a result of the action of the enzyme collagenase.

Collagen turnover is accelerated as old fibrous tissue is removed and as new fibrous tissue is formed. This process continues until the remodelling phase ends at six months to a year, depending on the state of the injury. The high rate of collagen turnover during this stage can be beneficial or detrimental. As long as the scar exhibits a rosier appearance than normal, remodelling is underway. However, it should be remembered that the speed of collagen synthesis and the laying down of new collagen is age-related and decreases with advancing years.

COLLAGEN FIBRE ORIENTATION

During the remodelling phase, collagen turnover allows the randomly deposited scar tissue to be arranged, in both linear and lateral orientation. Scar tissue is non-elastic and attempts to mimic the characteristics of the tissue that is undergoing the healing process. The tissue structure induces the collagen weave – dense tissues induce a dense, highly cross-linked scar, while pliable tissues induce a loose, coiled, less crosslinked scar. A scar can adapt through the remodelling forces of synthesis and lysis. Sometimes the process does not function as expected and results in unwanted scar tissue in the form of hypertrophic or keloid scars. These types of scar are the result of an overproduction of collagen, which causes the scar to be raised above the surrounding skin. ■

REFERENCES

- 1 *Taber's cyclopedic medical dictionary* 18th edn. Philadelphia: F.A. Davis Company, 1997. ISBN 0-8036-0195-6 or 0-8036-0193-x.
- 2 Thivierge B, Turkington CA. *Medical encyclopaedia online* www.answers.com/topic/wound?cat=health (accessed 30 November 2007).
- 3 Field FK, Kerstein MD. Overview of wound healing in a moist environment. *Am J Surg* 1994; **167**: 2S–6S.
- 4 Wijetunge DB. Management of acute and traumatic wounds: main aspects of care in adults and children. *Am J Surg* 1994; **167**: 56S–60S.
- 5 Baxter CR. Immunologic reactions in chronic wounds. *Am J Surg* 1994; **167**: 12S–14S.
- 6 Bolton LL, Monte K, Pirone LA. Moisture and healing: beyond the jargon. *Ostomy Wound Manage* 2000; **46**: 51S–62S; Quiz 63S–64S.
- 7 Smith DJ Jr, Thomson PD, Garner WL, Rodriguez JL. Donor site repair. *Am J Surg* 1994; **167**: 49S–51S.
- 8 Lawrence JC. Dressings and wound infection. *Am J Surg* 1994; **167**: 21S–24S.
- 9 Smith DJ Jr, Thomson PD, Garner WL, Rodriguez JL. Burn wounds: infection and healing. *Am J Surg* 1994; **167**: 46S–48S.
- 10 Metzger S. Clinical and financial advantages of moist wound management. *Home Healthc Nurse* 2004; **22**: 586–90.
- 11 Rheinecker SB. Wound management: the occlusive dressing. *J Athl Train* 1995; **30**: 143–6.
- 12 Hulten L. Dressings for surgical wounds. *Am J Surg* 1994; **167**: 42S–44S; Discussion 44S–45S.
- 13 Ferrell B, Coyle N. *Textbook of palliative nursing*. Oxford: Oxford University Press, 2001.
- 14 Atiyeh BS, Amm CA, El Musa KA. Improved scar quality following primary and secondary healing of cutaneous wounds. *Aesthetic Plast Surg* 2003; **27**: 411–7.
- 15 Atiyeh BS, Ioannovich J, Al-Amm CA, El-Musa KA, Dham R. Improving scar quality: a prospective clinical study. *Aesthetic Plast Surg* 2002; **26**: 470–6.
- 16 Kerstein MD. Introduction: moist wound healing. *Am J Surg* 1994; **167**: 1S.
- 17 Sochen JE. Orthopedic wounds. *Am J Surg* 1994; **167**: 52S–54S; Discussion 54S–55S.
- 18 Witte MB, Barbul A. Arginine physiology and its implication for wound healing. *Wound Repair Regen* 2003; **11** (6): 419–23.
- 19 Sauermann G, Uhlmann B, Gers-Barlag H, Hoppe U, Unna PG. Enhanced formation of sunburn cells after pretreatment with L-arginine/urea. Proceedings of the 19th IFSCC Congress, Sydney, Australia. October 1999. Paper R090.
- 20 Yamasaki K, Edington HDJ, McClosky T *et al*. Reversal of impaired wound repair in iNOS-deficient mice by topical adenoviral-mediated iNOS gene transfer. *J Clin Invest* 1998; **101** (5): 967–71.
- 21 Barbul A, Lazarou SA, Efron DT, Wasserkrug DT, Efron G. Arginine enhances wound healing and lymphocyte immune responses in humans. *Surgery* 1990; **108**: 331–7.
- 22 Kirk SJ, Hurson M, Regan MC, Holt DR, Wasserkrug DR, Barbul A. Arginine stimulates wound healing and immune function in elderly human beings. *Surgery* 1993; **114**: 155–60.
- 23 Regan MC, Barbul A. *The cellular biology of wound healing*. www.neuro.ki.se/neuro/KK2/Jimmy_GoogleCACHE1.html (accessed 5 December 2007)
- 24 Barbul A, Rettura G, Levenson SM. Arginine: a thymotrophic and wound promoting agent. *Surg Forum* 1977; **28**: 101–3.
- 25 Wittmann F, Prix N, Mayr S *et al*. L-arginine improves wound healing after trauma-hemorrhage by increasing collagen synthesis. *J Trauma* 2005; **59** (1): 162–8.
- 26 Arana V, Paz Y, Gonzalez A, Mendez V, Mendez JD. Healing of diabetic foot ulcers in L-arginine-treated patients. *Biomed Pharmacother* 2004; **58** (10): 588–97.
- 27 Peng X, Yi D, Fan SZ, *et al*. Analysis of the influence on the prognosis and safety of arginine in patients with severe trauma and burns – a multi-center randomized double blinded, placebo controlled, clinical trail in 86 patients (in Chinese). *Zhonghua Shao Shang Za Zhi* 2006; **22** (4): 243–6.
- 28 Laing P. Diabetic foot ulcers. *Am J Surg* 1994; **167**: 31S–36S.
- 29 Zitelli J. Wound healing for the clinician. *Adv Dermatol* 1987; **2**: 243–67.

Dr Pascal Mallefet works for Novartis Healthcare UK and Anthony C Dweck is technical editor of *Personal Care*. This article first appeared in the May 2008 issue and is reproduced here by kind permission.

GLOSSARY OF TERMS

Bradykinins

Bradykinins belong to a family of short, structurally similar peptides that are important metabolites of the kallikrein-kinin system. They are vasoactive nonapeptides formed by the action of proteases on the high-molecular-weight kininogen during the contact phase of blood coagulation, resulting in endothelium-dependent vasodilatation and stimulation of tissue plasminogen activator release from human endothelial cells. Bradykinin is released from mast cells in damaged tissues as a pain signal, and may act as a neurotransmitter. Bradykinin also contracts smooth muscles, and is a potent stimulator of nitric oxide formation by vascular endothelium. Bradykinin is involved in oedema resulting from trauma or injury and aids in dissolving blood clots. When it is secreted by eccrine sweat glands, it causes the surface of blood vessels to dilate and helps radiate excessive heat from the body surface, making it an important peripheral thermoregulatory molecule.

Chemotaxis

Chemotaxis is the phenomenon by which bodily cells, bacteria and other single-cell or multicellular organisms direct their movements according to certain chemicals in their environment. This is important for bacteria to find food (eg glucose) by swimming towards the highest concentration of food molecules, or to flee from poisons (eg phenol). In multicellular organisms, chemotaxis is critical to development as well as normal function. Chemotaxis is termed positive if movement is in the direction of a higher concentration of the chemical in question, and negative if the direction is opposite.

Collagenases

Collagenases are enzymes that break the peptide bonds in collagen. They assist in destroying extracellular structures in bacterial pathogenesis. They are an exotoxin (a virulence factor). Collagenase production can be induced during an immune response by cytokines that stimulate cells such as fibroblasts and osteoblasts, and cause indirect tissue damage.

Eschar

An eschar is a piece of dead tissue (scab) that is cast off from the surface of the skin, particularly after a burn injury, but it is also seen in gangrene, ulcers, fungal infections and late exposure to anthrax. Eschar is sometimes called a 'black wound' because the wound is covered with thick, dry, black necrotic tissue. Eschar may be allowed to slough off naturally, or it may require surgical removal (debridement) to prevent infection, especially in immunocompromised patients (eg if a skin graft is to be conducted).

Fibrinolysin

Fibrinolysis attacks and inactivates fibrin molecules occurring in undesirable exudates on the surface of the human body and on human mucosa (eg in superficial wounds and burns).

Fibroblast

Fibroblasts synthesise and maintain the extracellular matrix of many tissues. Fibroblasts provide a structural framework (stroma) for many tissues, and play a critical role in wound healing. They are the most common cells of connective tissue. The main function of fibroblasts is to maintain the structural integrity of connective tissue by continuously secreting precursors of the extracellular matrix. Fibroblasts secrete the precursors of all the components of the extracellular matrix, primarily the ground substance and a variety of fibres. The composition of the extracellular matrix determines the physical properties of connective tissues. Fibroblasts can also migrate slowly over the substratum as individual cells, again in contrast to epithelial cells. While epithelial cells form the lining of body structures, it is fibroblasts and related connective tissues that sculpt the bulk of an organism.

Hyaluronan

Hyaluronan (also called hyaluronic acid or hyaluronate) is a non-sulphated glycosaminoglycan distributed widely throughout connective, epithelial and neural tissues. It is one of the chief components of the extracellular matrix, and contributes significantly to cell proliferation and migration. Hyaluronan is also a major component of skin, where it is involved in tissue repair.

Hypertrophic scar.

Two types of scars are the result of the body overproducing collagen, which causes the scar to be raised above the surrounding skin. Hypertrophic scars take the form of a red raised lump on the skin, but do not grow beyond the boundaries of the original wound, and they often improve in appearance after a few years. The other type is a keloid scar.

Intussusceptive growth

Intussusceptive growth is the folding in of an outer layer to form a pocket in the surface. It is the growth in the surface area of a cell by the deposit of new particles between existing particles in the cell wall.

Keloid scar

A keloid is the result of an overgrowth of tissue at the site of a healed skin injury. Keloids are firm, rubbery lesions or shiny, fibrous nodules and can vary from pink to flesh-coloured or red to dark brown in colour. A keloid scar is benign, non-contagious and usually accompanied by severe itchiness, sharp pains

and changes in texture. In severe cases, it can affect the movement of skin. Keloids should not be confused with hypertrophic scars, which are raised scars that do not grow beyond the boundaries of the original wound and may reduce over time.

Lytic cycle

The lytic cycle is one of the two cycles of viral reproduction, the other being the lysogenic cycle. These cycles should not be seen as separate, but rather as interchangeable. The lytic cycle is typically considered to be the main method of viral replication, as it results in the destruction of the infected cell.

Macrophage

Macrophages are cells in tissue that originate from specific white blood cells called monocytes. Monocytes and macrophages are phagocytes, acting in both non-specific defence (innate immunity) and specific defence (cell-mediated immunity) in vertebrate animals. Their role is to phagocytose (engulf and then digest) cellular debris and pathogens either as stationary or mobile cells, and to stimulate lymphocytes and other immune cells to respond to the pathogen.

Neovascularisation

Neovascularisation is the formation of functional microvascular networks with red blood cell perfusion, and differs from angiogenesis in that the latter is characterised mainly by the protrusion and outgrowth of capillary buds and sprouts from pre-existing blood vessels.

Phagocytosis

Phagocytosis is the cellular process of engulfing solid particles by the cell membrane to form an internal phagosome (food vacuole). The phagosome is usually delivered to the lysosome, an organelle involved in the breakdown of cellular components, which fuses with the phagosome. The contents are subsequently degraded and either released extracellularly via exocytosis, or released intracellularly to undergo further processing. Phagocytosis is part of the immune system and is a major mechanism used to remove pathogens and cell debris. Bacteria, dead tissue cells and small mineral particles are all examples of objects that may be phagocytosed.

Prostaglandin

Prostaglandin is one of a number of hormone-like substances that participate in a wide range of body functions such as the contraction and relaxation of smooth muscle, the dilation and constriction of blood vessels, control of blood pressure, and the modulation of inflammation. Prostaglandins are derived from arachidonic acid.